

CUTERA[®] Laser & Light / Modular & Evolving

Fine Lines / Texture

3D

Pearl

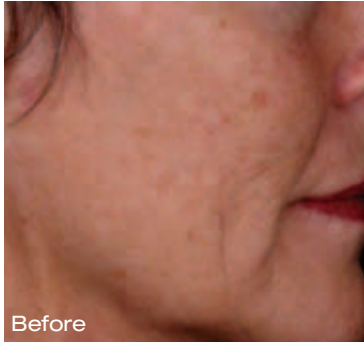Laser Genesis

Lentiginos

Cheek

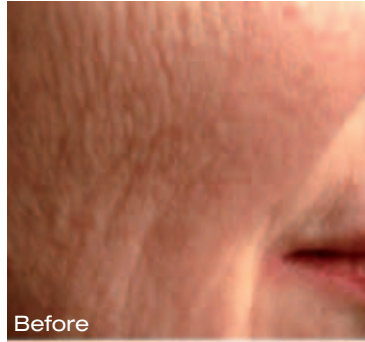
Periocular

Pore Size & Texture



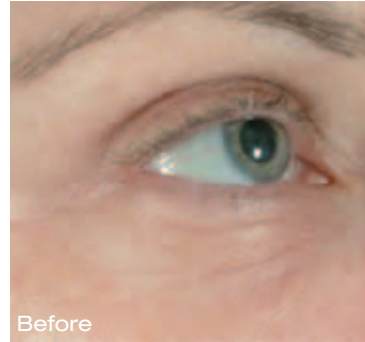Before

Photo courtesy of E. Vic Ross, MD



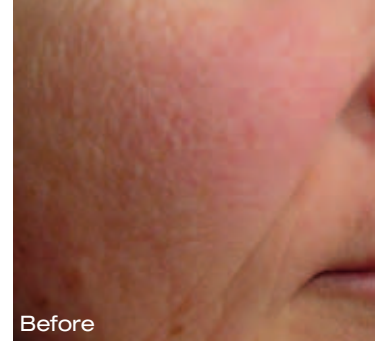Before

Photo courtesy of Maritza Perez, MD



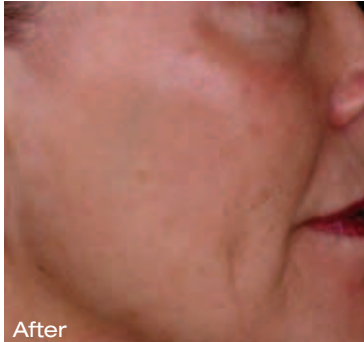Before

Photo courtesy Amy Taub, MD



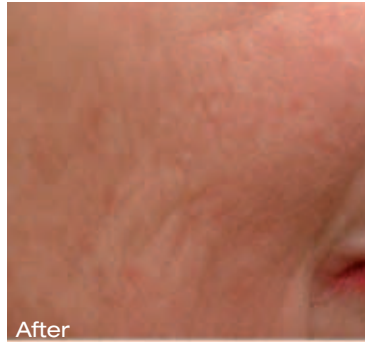Before

Photo courtesy of Kevin Smith, MD



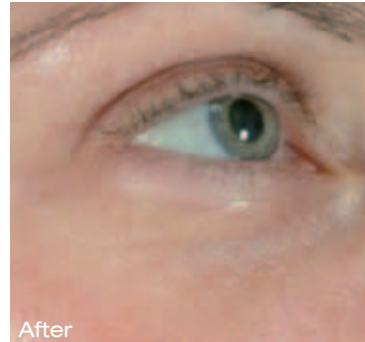After

28 days after second Tx



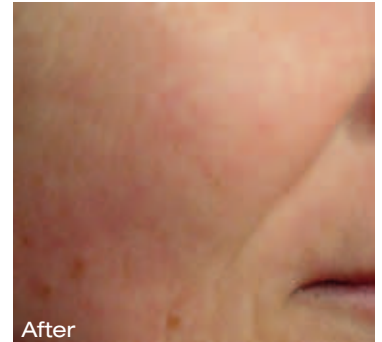After

2 weeks after 1st Tx



After

one week after 1st Tx



After

7 weeks after 6th Tx

Laxity / Tightness

3D

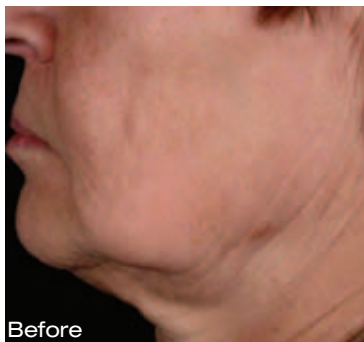
Titan

Neck

Neck

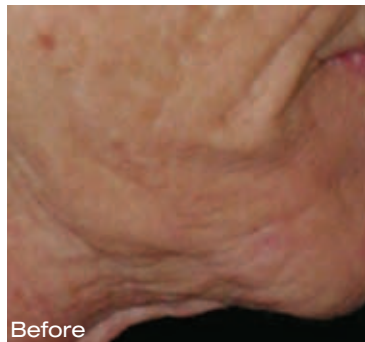
Neck

Abdomen



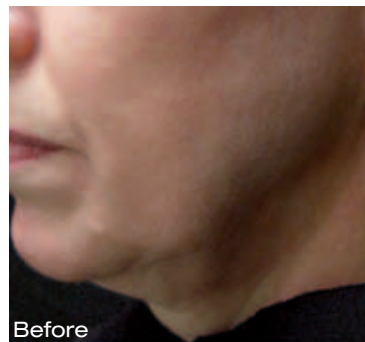
Before

Photo courtesy of David Goldberg, MD



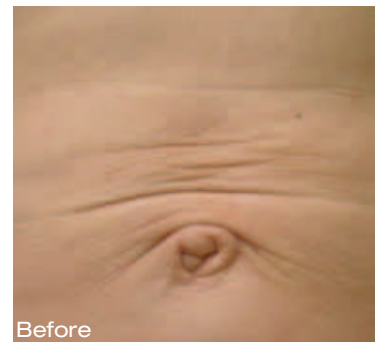Before

Photo courtesy of Dr. Javier Ruiz-Esparza, MD



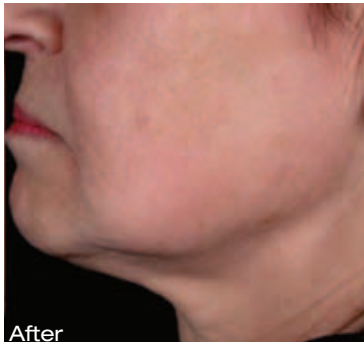
Before

Photo courtesy of Bruce Russel, MD



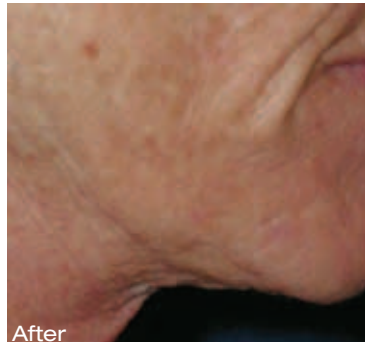
Before

Photo courtesy of M. Don Groot, MD



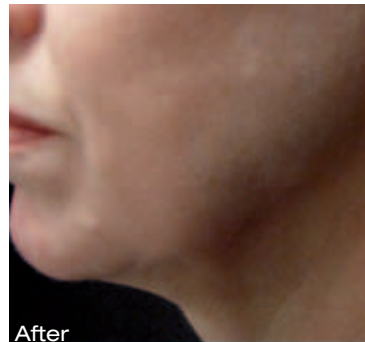
After

three months after 2nd Tx



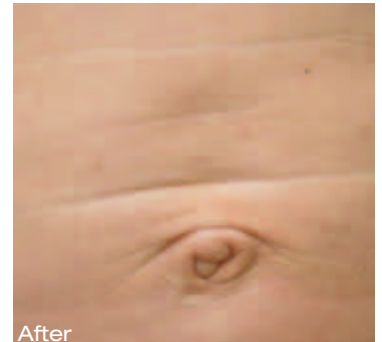After

after 1st Tx



After

after 2nd Tx



After

1 month after 2nd Tx

Facial Vascular

1064 Vascular

LimeLight

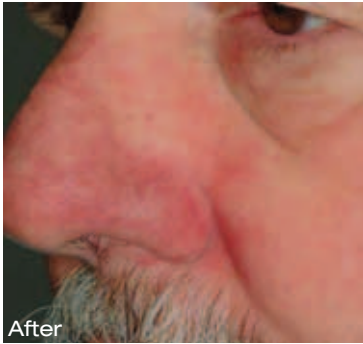AcuTip 500

Facial Telangiectasia



Before

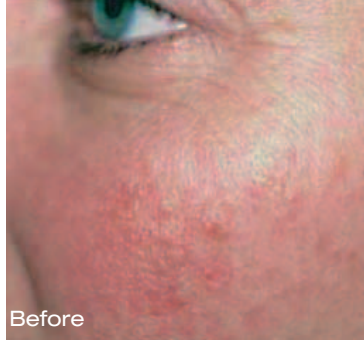Photo courtesy of E. Vic Ross MD



After

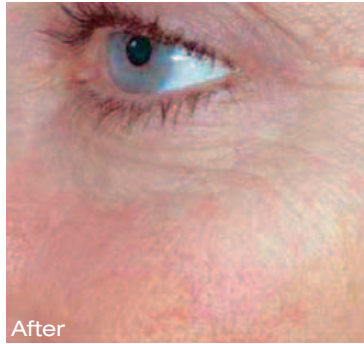
after 1st Tx

Redness, Skin Texture



Before

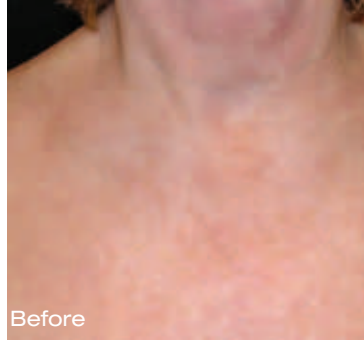Photo courtesy of David Goldberg, MD



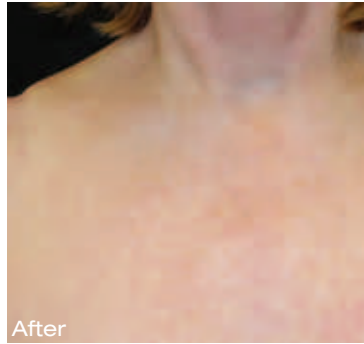After

three months after 3ed Tx

Chest



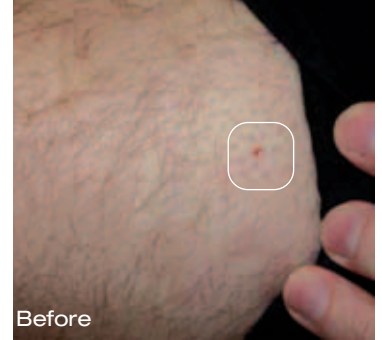
Before



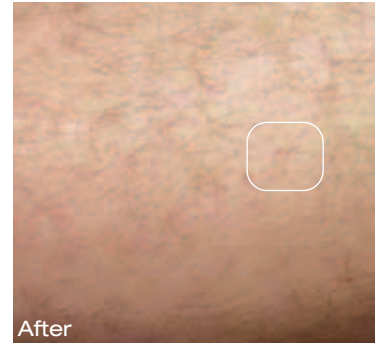After

2 weeks after 2st Tx

Cherry Hemangioma



Before



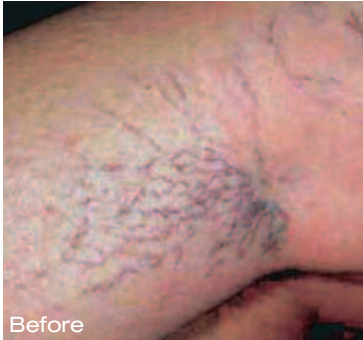After

after 1st Tx

Leg Veins

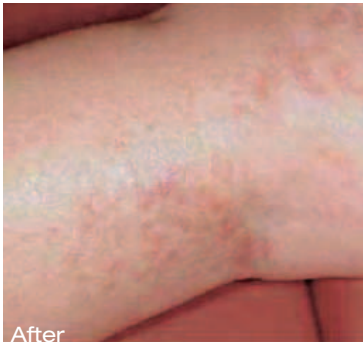1064 Vascular

Leg Veins



Before

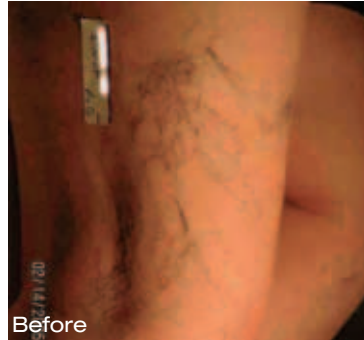Photo courtesy of Leonardo Rasi, MD



After

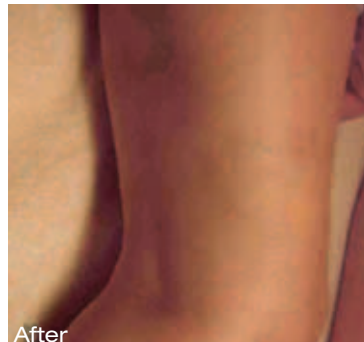
after 2nd Tx

Leg Veins



Before

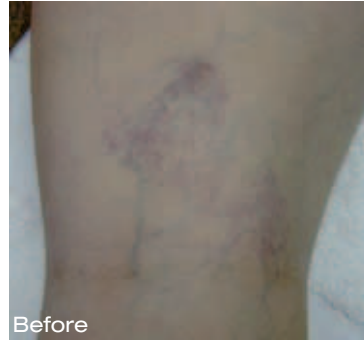Photo courtesy of Debbie Caddell, MD



After

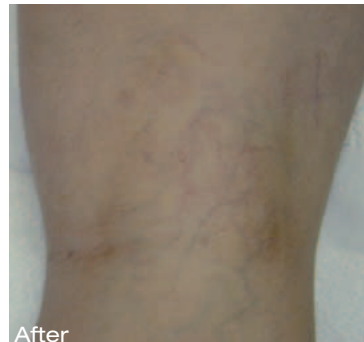
5 weeks after 5th Tx

Leg Veins



Before

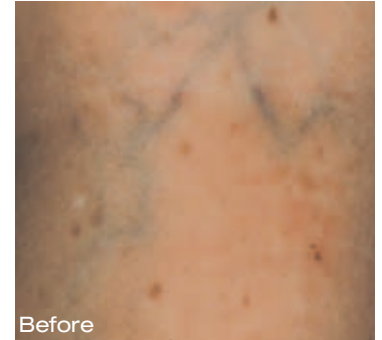Photo courtesy of Samuel Ledermann, MD



After

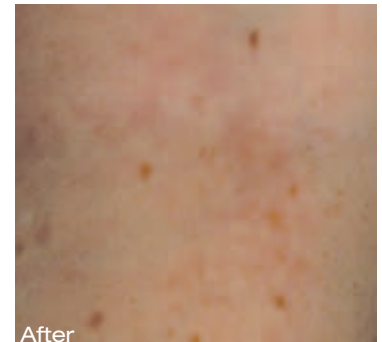after 1st Tx

Leg Veins



Before

Photo courtesy of Arielle Kauvar, MD



After

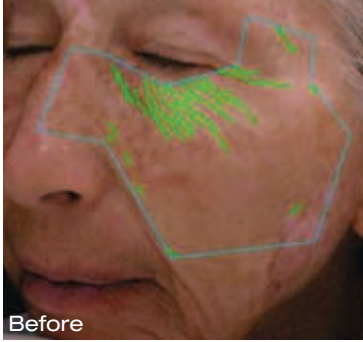
after 1st Tx

Pigment /Tone

3D

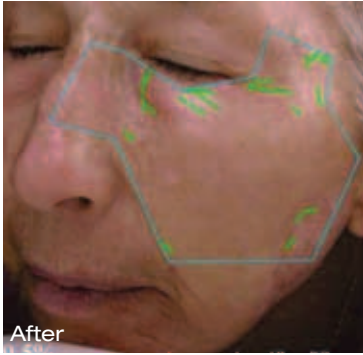
Pearl

Fine Lines



Before

Photo courtesy of Barry DiBernardo, MD

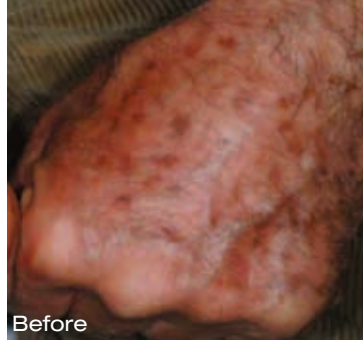

After

30 days after 1 Tx

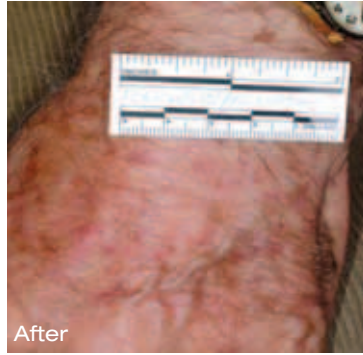AcuTip 500

Solar Lentigin



Before

Photo courtesy of E. Vic Ross, MD

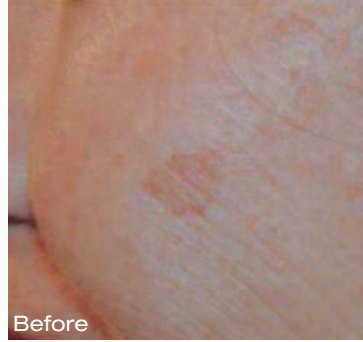


After

three months after 1st Tx

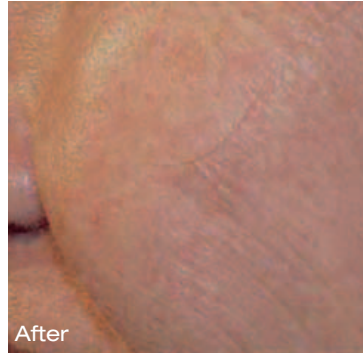
LimeLight

Pigmented Lesion



Before

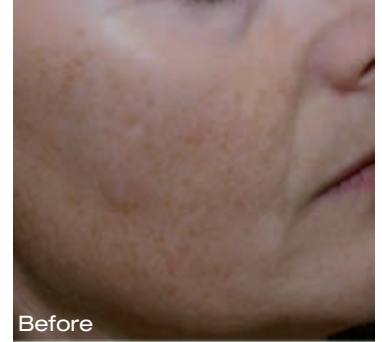Photo courtesy of Bruce Russel, MD



After

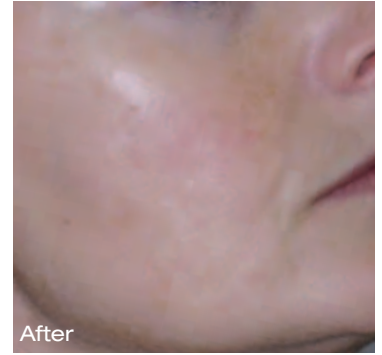4 weeks after 2 Tx

Sun Damage



Before

Photo courtesy of Maurice Adatto, MD



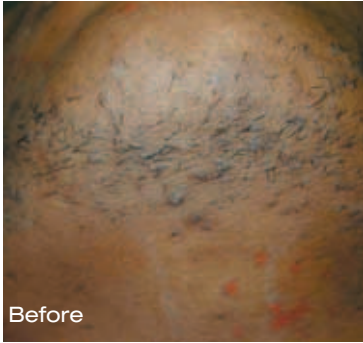After

2 weeks after 1st Tx

Hair Removal

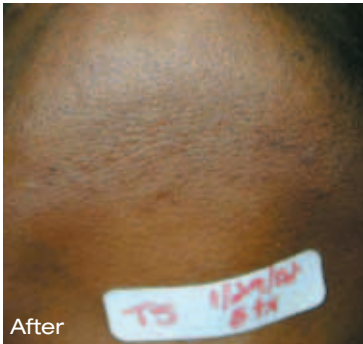1064 Hair Removal

Chin



Before

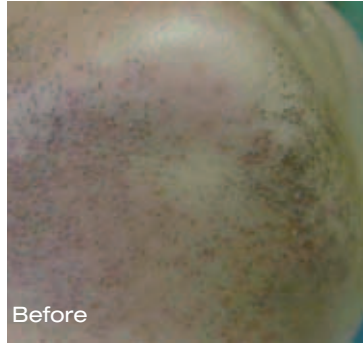
Photo courtesy of Samuel Ledermann, MD



After

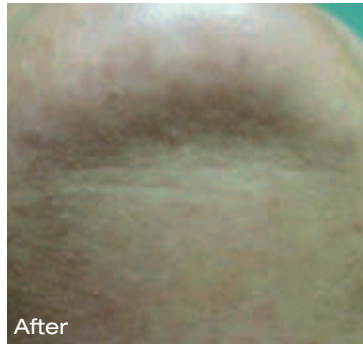6 weeks after last treatment

Chin



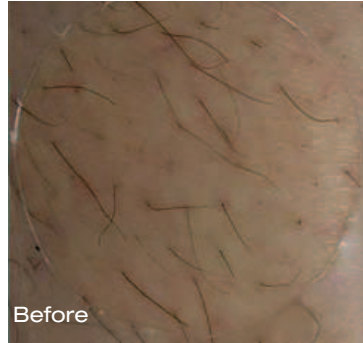
Before

Photo courtesy of Samuel Ledermann, MD



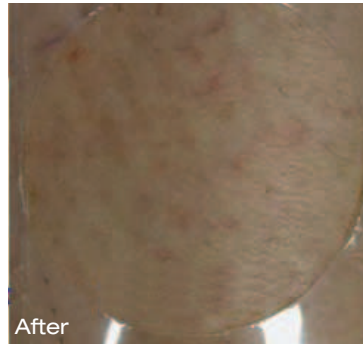
After

Leg



Before

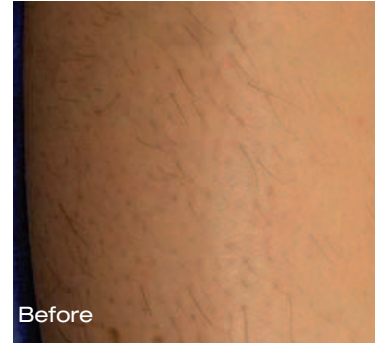Photo courtesy of Kei Negishi, MD



After

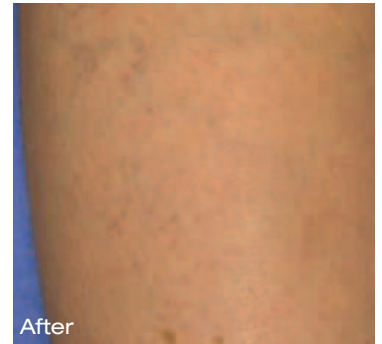
6 months after 3ed Tx

Leg



Before

Photo courtesy of Kei Negishi, MD



After

6 month after 3ed Tx.



LimeLight Facial

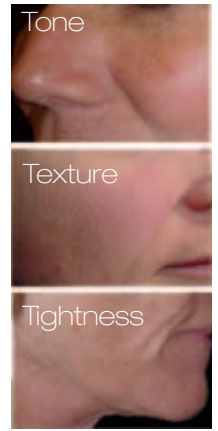
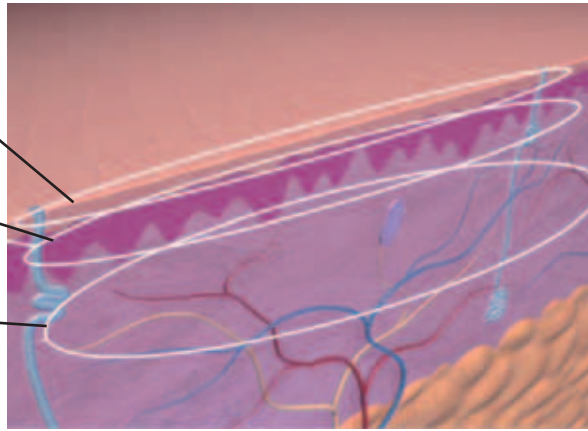
520 - 1100 nm
Red & Brown Dyschromia
Telangiectasia

Laser Genesis

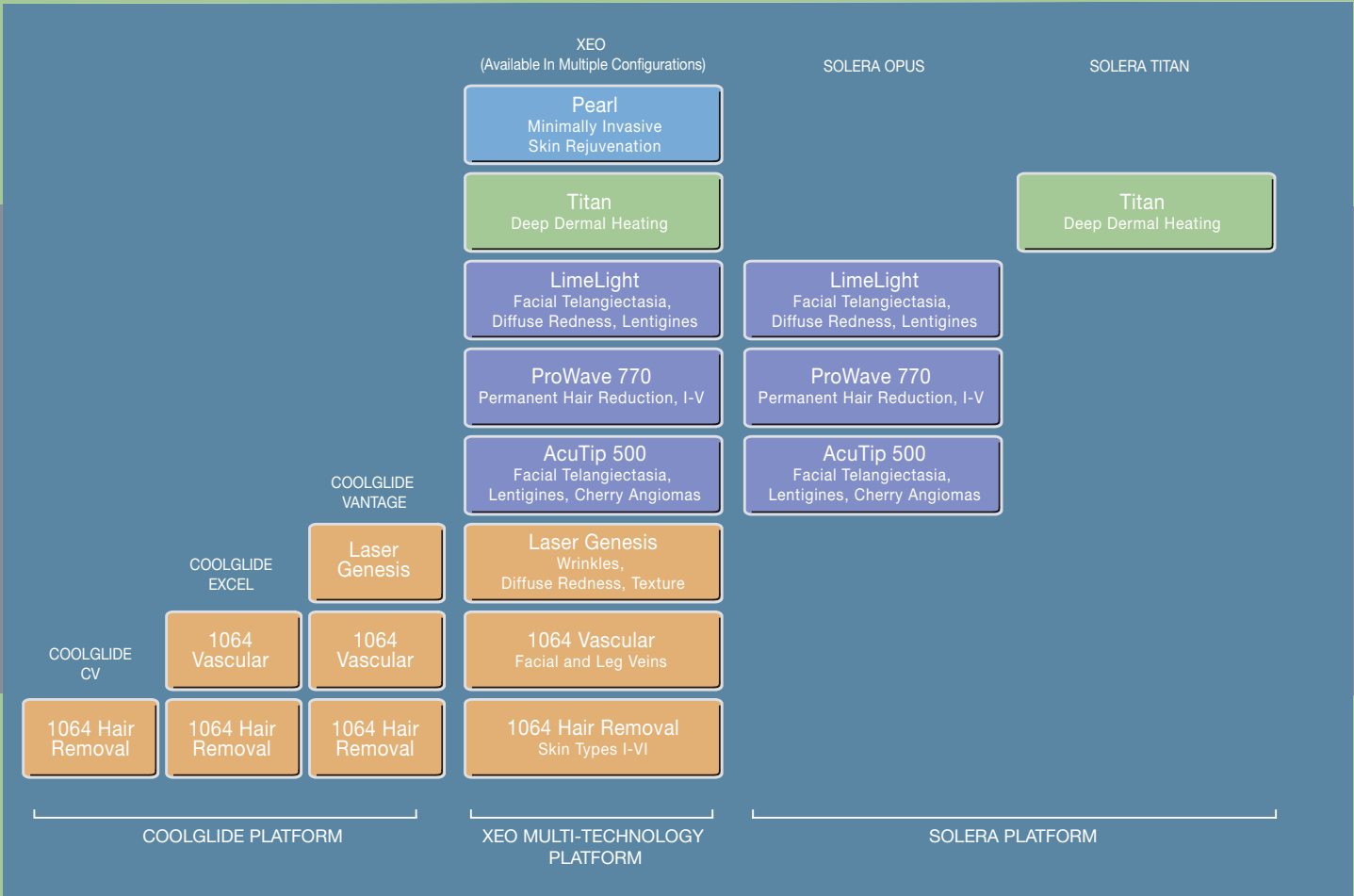
Microsecond 1064 nm
Treats pore size, texture and fine lines

Titan

Tailored infrared spectrum



Technology Solutions



Cutera, Inc.
World Headquarters
3240 Bayshore Boulevard
Brisbane, CA 94005 USA
Tel: +1 415 657 5500
Fax: +1 415 330 2444

Cutera (Europe)
Industriestrasse 19
8304 Wallisellen ZH
Switzerland
Tel: +41 (0) 43 233 73 73
Fax: +41 (0) 43 233 73 50

Cutera (Asia Pacific)
Giraffa Building 11th floor
1-6-10 Hiroo
Shibuya-ku, Tokyo 150-0012
Tel: +81 (0) 3 3473 9180
Fax: +81 (0) 3 3473 9181