

# Clinical and Histological Results of Full Face Treatments with the 2,790 nm Pearl Fractionated YSGG Laser System

E. Victor Ross, MD, Richard Green, MD and Leonardo Rasi, MD

*Dermatology Division, Scripps Clinic  
San Diego, CA*

*Salmon Creek Plastic Surgery  
Vancouver, WA*

*Senza Aesthetic Medicine  
Redlands, CA*

---

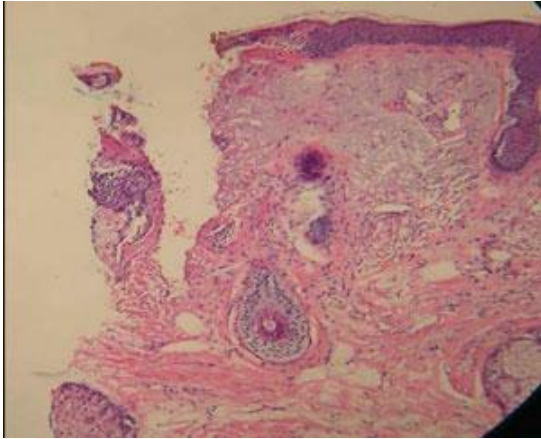
## **Background**

Safe and effective fractional ablative laser treatments require a solution that ablates a narrow column of tissue well into the dermis, provides the thermal benefits of operative coagulation and long term collagen stimulation while minimizing complications associated with excessive thermal damage lateral to the ablated tissue. The dominant variable to control these thermal characteristics is wavelength. With these requirements in mind, a wavelength of 2790nm was chosen for this study. This novel wavelength has a coefficient of water absorption well suited to regulate depth and volume of ablation, provide operative coagulation and stimulate collagen.

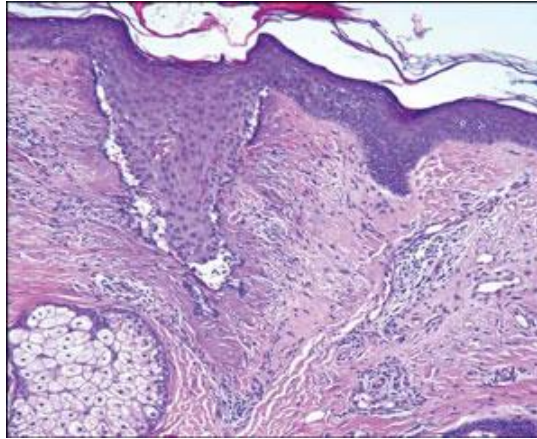
This paper reports preliminary results from a study to evaluate the safety, efficacy and histological effects from treatments with this new device.

**Study Design/Material and Methods:** This was an institutional review board approved study of 30 subjects from three independent investigator sites. Subjects included Fitzpatrick skin type I-III with mild to severe wrinkles (Fitzpatrick wrinkle severity scale 3 to 7) between 43 and 73 years of age. Each subject received a single full-face treatment of fractionated 2790 nm irradiation (Pearl Fractional, Cutera, Brisbane, CA). Treatment energies varied from 160mJ to 240mJ per micro spot. The 300 micron diameter micro spots were applied with a medium density pulse pattern in all but one treatment. Treatments consisted of single or double pass full-face doses depending on skin type and wrinkle severity. An additional pass was performed over wrinkles for some subjects. Pain management was achieved via topical application of 7% lidocaine and 7% tetracaine cream at least 45 minutes prior to treatment. Additional anesthesia, including nerve blocks or cold air was used at the discretion of the physician. Randomly selected subjects received biopsies immediately following treatment, 4-days post treatment and two weeks post treatment. Follow up visits were scheduled 1 day, 3 to 7 days, 10 days, and 1-month post treatment. Final outcome measurements were recorded at least 1 month post treatment using a 4-point subject self-assessment score (1 = no improvement, 2= mild improvement, 3 = significant improvement, 4 = dramatic improvement) and a 5-point overall treatment satisfaction scale (1 = unhappy, 2= pleased, 3 = happy, 4 = very happy, 5 = extremely happy).

**Results:** All 30 subjects received treatment. At the time of publication, 16 subjects completed their 30-day post treatment follow up visits. Treatment time for full-face ranged from 40 to 70 minutes. Histology showed complete re-epithelialization at the day four biopsy.



Immediately after 160mJ/micropulse



4 days post treatment

No incidences of hyperpigmentation or infections were observed. Biopsies showed a 300 micron diameter spot size with increasing depth of ablation with escalating energy settings. The depths of ablation were 600–1000 microns and the amount of peripheral thermal damage surrounding the zone of ablation was 40 microns. Mild pinpoint bleeding and oozing occurred in some treatment areas during the procedure and, was reported to persist for 7 to 12 hours after treatment. Increased energy levels (240 mJ) were associated with slightly elevated levels of intra- and post-operative oozing. No patients reported active weeping or oozing 24-hours post treatment. All patients treated with the medium density setting, regardless of treatment at 160mJ or 240 mJ, were able to start wearing make-up between 5 and 7 days after treatment. Edema was notable during the first few days after treatment. For subjects who had previously undergone rhytidectomy, edema persisted three days longer on average. No significant increase in downtime was noted as a result of a second or third pass utilizing the medium density setting (per pass). Patients treated with 240mJ energy levels experienced slightly longer periods of erythema, edema and a delay in healing in some individual spots. One patient treated with a single pass at the highest density setting experienced increased recovery. Based on the treating physicians' experiences, pain levels during treatment were similar to those associated with other fractional ablative laser devices. Overall, treatments at both energy levels were well tolerated. Subjects reported the following:

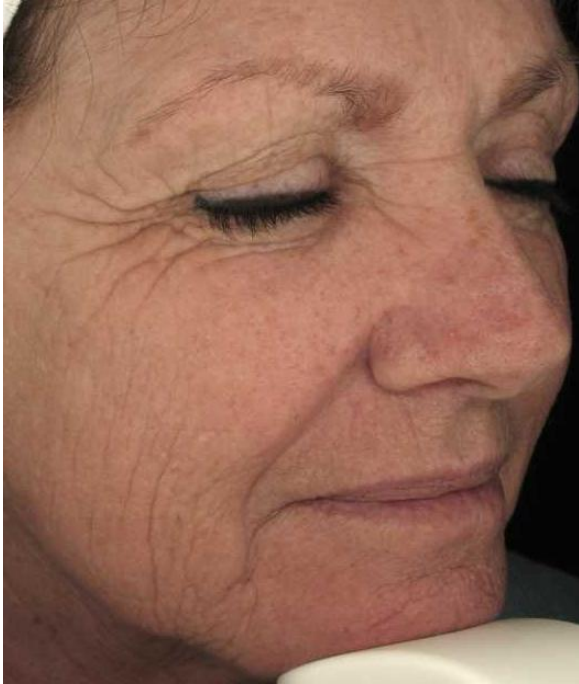- 15 of 16 subjects would recommend Pearl Fractional to a friend
- 88% were 'happy' to 'extremely happy' with their treatment results
- 57% of subjects reported significant to dramatic improvement in wrinkles
- 75% reported significant to dramatic improvement in fine lines
- 76% reported significant to dramatic improvement in skin tone-texture

**Discussion:** The 2790 nm YSGG laser offers a high yield of cosmetic enhancement with minimal downtime. The controlled thermal damage provided by this device enables deep and high-volume dermal ablation without excessive bleeding or increased risk of complications from excessive thermal damage.

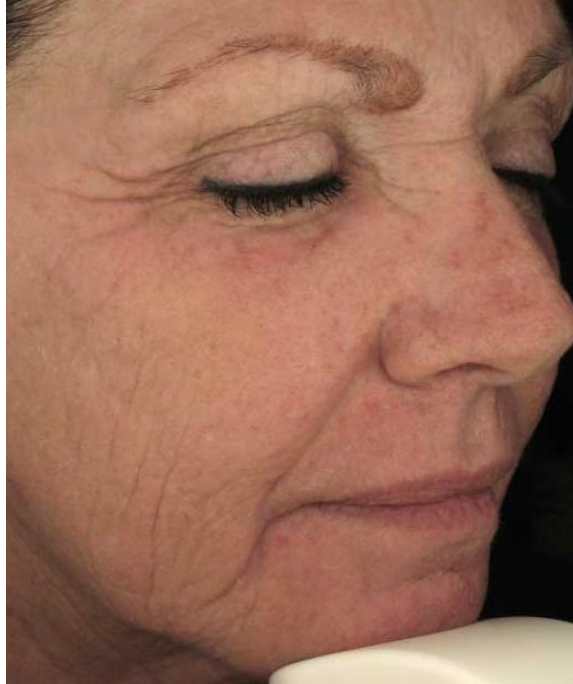Based on the treatment outcomes, wrinkle improvement appeared to be more correlated with increased density (in the form of multiple passes) than increased energy (depth). However, acne scars or severe wrinkles may warrant higher energy settings.

This study also demonstrated that the high density setting is more aggressive than multiple passes utilizing the medium density setting leading to significantly longer recovery. It is therefore recommended that the high density setting be used only by experienced clinicians on select patients. Additional data is currently being gathered to corroborate these findings.

Patient A: 62 year old female, skin type II, perioral and periorbital areas: 160mJ, high density, single pass; other areas: 240mJ, medium density, single pass

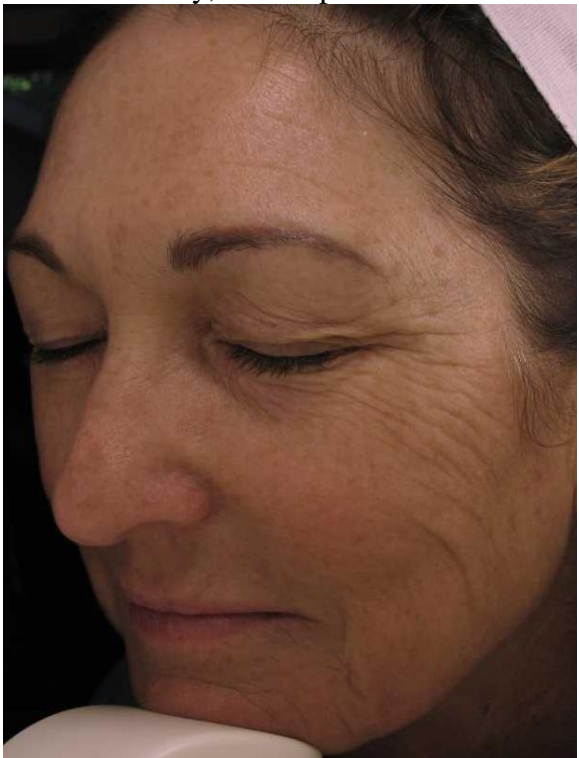


Before

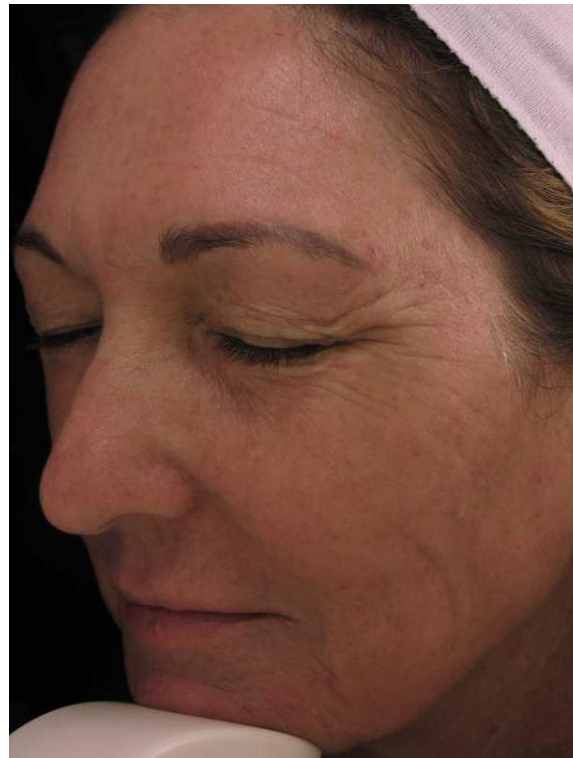

30 days post 1 treatment

Patient B: 51-year old female, skin type II, perioral area: 240mJ, medium density, double pass; other areas: 160mJ, medium density, double pass

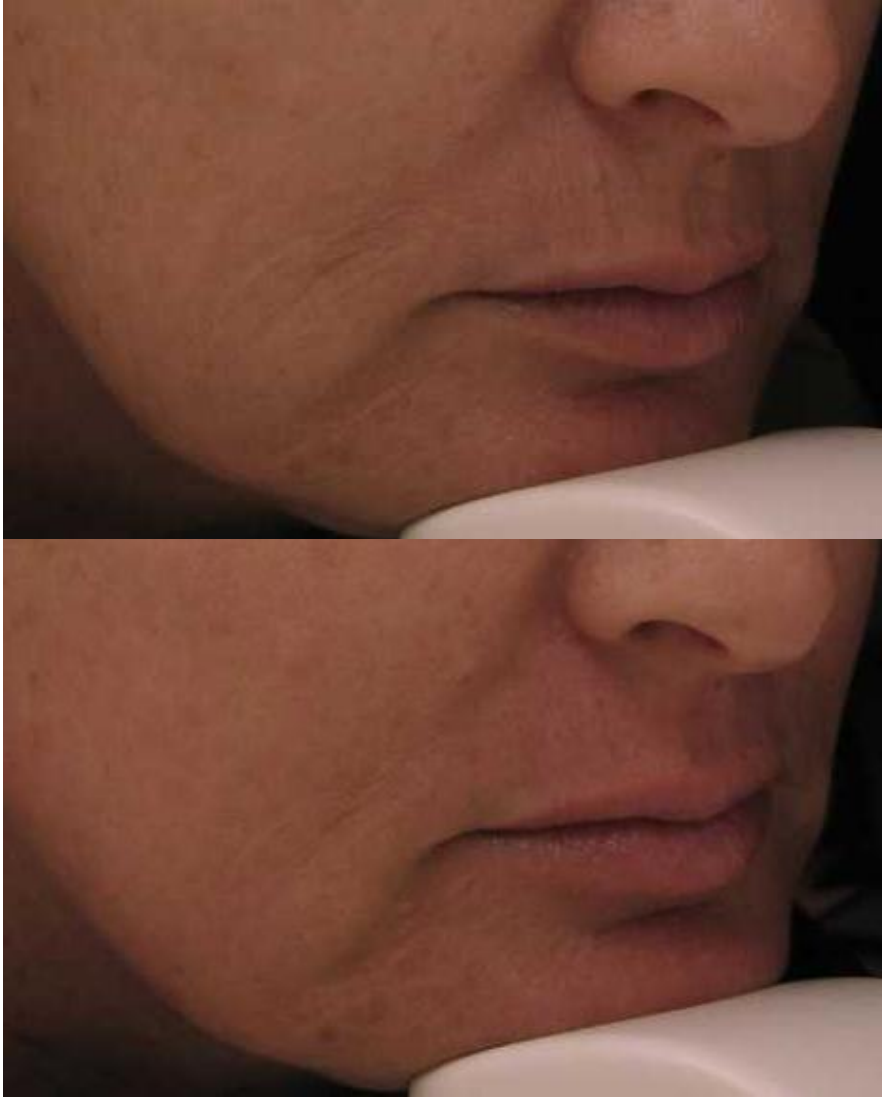

Before



14 days post 1 treatment

Patient C 51-year old female, skin type II, perioral and periorbital areas: 240mJ, medium density, double pass; other areas: 240mJ, medium density, single pass



Before and 28 days post 1 treatment

**About the Physicians:**

E. Victor Ross, MD is a board-certified dermatologist and currently the director of the Laser and Cosmetic Dermatology Unit at Scripps Clinic in San Diego. He is also on the teaching staff at the University of California, San Diego. Dr. Ross is the president of the American Society of Laser Medicine and Surgery also known as ASLMS. He completed his dermatology residency at the National Naval Medical Center and performed a two-year fellowship in photomedicine at the prestigious Wellman Laboratories and Massachusetts General Hospital Dermatology Laser Center. He was honored in 2001 as the Navy recipient of the Chairman Joint Chief of Staff Award for Excellence in Military Medicine.

Richard Green, MD, FACS practices general plastic surgery and surgery of the hand in Vancouver, Washington. A graduate of the University of Illinois College of Medicine, Dr. Green trained in General Surgery and Plastic Surgery at Loyola University in Maywood, Illinois. He then completed a fellowship in Hand and Microvascular Surgery at the University of Utah. Dr. Green has been in private practice for 12 years, and he incorporated laser services into his aesthetic practice six years ago.

Leonardo Rasi, MD received his MD from Loma Linda University School of Medicine where he went on to complete two years of surgical training before devoting his practice to laser and cosmetic medicine. This is his tenth year in private practice at Senza Aesthetic Medicine.

### **Bibliographic References**

Manstein D, Herron GS, Sink RK, et al. Fractional photothermolysis: a new concept for cutaneous remodeling using microscopic patterns of thermal injury. *Lasers Surg Med* 2004; 34:426-438.

Geronemus, RG. Fractional photothermolysis: current and future applications. *Lasers Surg Med* 2006; 38(3): 169-176.

Fisher G, Kim KH, Bernstein LJ, Geronemus RG. Concurrent use of a handheld forced cold air device minimizes patient discomfort during fractional photothermolysis. *Dermatol Surg* 2005; 31:1242-1244.

Hantash BM, Vikramaditya PB, Bhumika K, et al. In vivo histological evaluation of a novel ablative fractional resurfacing device. *Lasers Surg Med* 2007; 39:96-107.

Fisher GH, Geronemus RG. Short-term side effects of fractional photothermolysis. *Dermatol Surg* 2005; 31:1245-1249.

Bedi VP, Chan KF, Sink RK, Hantash BM, Herron GS, Rahman Z, Struck SK, Zachary CB. The effects of pulse energy variations on the dimensions of microscopic thermal treatment zones in fractional photothermolysis. *Lasers Surg Med* 2007; 39(2):145-155.

DiBernardo B. Assessment of the impact of high-fluence, high-overlap settings on full face treatments with the 2,790nm Pearl YSGG laser. As presented at ASLMS 2008.

Ross EV. Erbium YSGG laser in facial rejuvenation. As presented at ASLMS 2008.